

# Ovariectomy on Ultrastructure of Meibomian Gland Epithelial Cells in Rats

Jinli Liang  
Baolai Li  
Na Han

Jinli Liang Department of Obstetrical, Qingdao Chengyang People's Hospital, Qingdao 266000, Shandong, China, Baolai Li Department of Obstetrics, Qingdao City Hospital, Qingdao 266011, Shandong, China, Na Han\* Department of Obstetrics, Qingdao Women and Children's Hospital, Qingdao 266011, Shandong, China, \*Corresponding author (E-mail: [abcyuqing@163.com](mailto:abcyuqing@163.com))

Dry eye mainly occurs in perimenopausal women, perimenopausal women with ovarian atrophy, estrogen and androgen levels showed a significant downward trend, and androgen related Estrogen Progesterone and prolactin receptors are widely distributed in lacrimal gland, meibomian gland, cornea and other tissues. The purpose of this study was to investigate the effect of ovariectomy on the ultrastructure of meibomian gland epithelial cells in rats. At the same time, we used the laboratory experiment method to select the non ovariectomized rats and ovariectomized rats were divided into two groups. After ovariectomy, we studied the effect of ovariectomy on the ultrastructure of meibomian gland epithelial cells in rats. objective to investigate the curative effect of palpebral margin in the treatment of moderate and severe meibomian gland dysfunction. The results showed that the ultrastructure of meibomian gland epithelial cells had obvious pathological changes after ovariectomy. It can improve 90% of female patients' subjective symptoms and severity, increase tear secretion and reduce corneal fluorescein staining, reduce tear film damage, enhance the stability of tear film, and restore meibomian gland function. The treatment effect is significant. It can lay the foundation for the future clinical treatment of meibomian gland dysfunction and other related dry eyes, and it can also become an effective new treatment for postmenopausal women.

**Keywords:** Ovariectomy Experiment, Meibomian Gland, Ultrastructure, Meibomian Gland Dysfunction

*Tob Regul Sci.*™ 2021;7(5-1): 3418-3427

DOI: [doi.org/10.18001/TRS.7.5.1.118](https://doi.org/10.18001/TRS.7.5.1.118)

Meibomian gland dysfunction is a common, slow and complex eye disease. It is a multifactorial eye surface and lacrimal duct disease. It can cause eye discomfort, visual impairment, tear film instability and damage the eye surface. With the increase of tear film permeability and surface inflammation, the eye will be damaged. It is a public health problem that has been Xerophthalmia concerned and has affected about 20% - 30% of adults. Dry eye disease may lead to foreign body sensation, burning sensation, pain, photophobia and vision fluctuation in the eyes of patients, or secondary ocular surface infection, corneal opacity, ulcer, neovascularization, or even corneal perforation and blindness. Dry eye caused by dry eye foreign body sensation, burning sensation seriously affect the quality of life and physical and mental health of ordinary people. The risk factors of dry eye disease include old age, postmenopausal

women, smoking history, too cold or too hot environment, low humidity, long-term use of video terminals, ocular surface nerve injury and tear film stability reduction caused by eye surgery, long-term wearing of contact lenses and use of certain drugs.

Estrogen plays an important role in maintaining the structure and function of lacrimal gland. Androgen is involved in maintaining tear film stability by regulating lacrimal gland secretion. The decrease of estrogen level can cause lacrimal gland cell apoptosis, necrosis and lymphocyte infiltration. Estrogen can up regulate the expression of MMP-9 and MMP-2 in lacrimal gland of ovariectomized rabbits, and then participate in the pathogenesis of dry eye. Estrogen can play its anti-inflammatory role by promoting T cell apoptosis, blocking toll like receptor, inhibiting nuclear factor and promoting glucocorticoid secretion, and interfere with the

occurrence and development of many diseases. The incidence of dry eye is related to the decrease of sex hormone levels and the imbalance of the ratio. The international working group of MGD reported that the prevalence of MGD in the world is between 3.5% and 69.3%, with the highest prevalence in Chinese mainland. The prevalence rate among people over 40 is between 68% and 69.3%. MGD may cause excessive evaporation of tear, reduce the stability of tear film, cause dry eye, inflammation, epithelial injury, etc. A series of pathophysiological changes, and then destroy the ocular surface barrier, affect the prognosis of eye surgery, reduce the quality of life of people.

Meibomian gland is a dense connective tissue located in the inner side of the eyelid, which is half moon shaped. It is embedded in the meibomian opening and located at the edge of the meibomian. The lipid secreted by meibomian gland will form the surface of tears, which is necessary to prevent excessive evaporation of tears. Abnormal secretion of meibomian gland blocked meibomian gland opening. Veronesi in addition, genistein and / or silicon treatment decreased serum alkaline phosphatase and osteocalcin, and increased serum ALP and osteocalcin after ovariectomy. This indicates that genistein and silicon have synergistic effect on bone formation in ovariectomized rats, but there is no specific data<sup>1</sup>. Owusu C believes that the interleukin family plays a key role in the pathogenesis of rheumatoid arthritis and osteoporosis by regulating bone formation and bone resorption. Sp-ee can inhibit the phosphorylation of MAPK and Akt, and the expression of NFATc1 and osteoclast marker genes. RANKL can inhibit the differentiation of osteoclasts. EN inhibits the bone resorption activity of osteoclasts, but there is no necessary experimental data<sup>2</sup>. Duffy s believes that the purpose of this study is to study the protective effect of Polysaccharide from *Staphylococcus aureus* on osteoporosis rats induced by ovariectomy. The changes of body weight, bone mineral content, bone mineral density, failure load, histological characteristics and histomorphological indexes were observed. In particular, serum osteocalcin, bone specific alkaline phosphatase, calcium and

phosphorus levels and urinary deoxypyridine / creatinine ratio were measured. One group of rats used alendronate sodium as control drug. Dorikang can inhibit the changes of bone resorption and bone turnover induced by ovariectomy in a dose-dependent manner. The expression level of serum BALP and histomorphometric indexes of bone formation in polysaccharide treatment group were significantly increased. It is suggested that PPS can maintain bone quality and strength and improve bone formation rate of OVX rats, suggesting that PAH may be a potential anti rheumatic drug, but there is a lack of numerical analysis<sup>3</sup>. Vogel V G It is considered that the end tidal concentration of isoflurane required to maintain heart rate and respiratory rate in ovariectomized cats receiving buprenorphine, tramadol or a combination of them is within  $\pm 20\%$  of the basic measured value. Compared with the isoflurane concentration measured during skin incision and suture, ovarian pedicle traction caused a statistical increase in end tidal isoflurane concentration, and no difference was observed between the operation time points It is speculated that there may be hyperadditive interaction between tramadol and buprenorphine in cats, but some discussions are not accurate<sup>4</sup>.

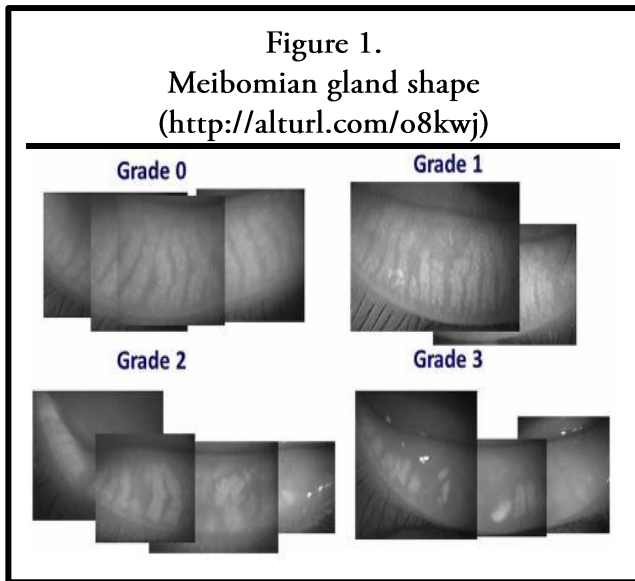
The innovation of this paper is to use the experimental investigation method, select the non ovariectomized rats and ovariectomized rats are divided into two groups, through the comparative observation of bone marrow gland epithelial cells of experimental rats, reveal the influence of ovarian anemia on ultrasound. objective to study the effect of ovariectomy on the ultrastructure of meibomian gland epithelial cells in rats, and lay a certain foundation for improving female pain and the quality of life of patients in the future<sup>5,6</sup>.

## METHODS OF MEIBOMIAN GLAND EPITHELIAL CELLS

### Meibomian Gland

In the 2nd century BC, galenas first mentioned meibomian gland. It was not until 1666 that Heinrich MEBO systematically described meibomian gland, which was systematically described as meibomian gland<sup>7,8</sup>. Meibomian gland is the largest selfish gland in the human body. It

synthesizes and secretes lipids and participates in the formation of ice film. It has many functions: (1) to create a smooth and flat optical interface for the root; (2) to reduce the tear vapor; (3) to reduce the pressure on the tear surface and increase the stability of the tear film; (4) to support the diffusion of the tear film; (5) to prevent the tear from passing through the vertical movement of the eyelid edge Use <sup>9, 10</sup>. Meibomian gland dysfunction is a kind of chronic diffuse meibomian gland abnormality,



which is usually characterized by terminal duct obstruction and changes in meibomian gland secretion. With the change of society, the change of people's working environment and lifestyle, the popularity of video terminals such as computers and smart phones, the aggravation of environmental pollution and other factors <sup>11, 12</sup>. The expansion of the millennium development goals is increasing year by year and tends to be younger. Some studies show that about 20% to 55% of normal people have abnormal e-mail, as shown in Figure 1:

**Quantification of Meibomian Gland**

**BN probability theory**

The structure of tear film of meibomian gland was first proposed <sup>13</sup>. Although the tear membrane structure model is too simple, it has been used in clinical practice. It is inseparable from probability theory that the quantitative study of BN is inseparable from that of BN <sup>14,15</sup>. It can be said that the basis of BN quantification is probability theory such as

formula:

$$output = f(h^T x + a) = (\sum_{i=1}^n h_i x_i + a) \quad (1)$$

The destruction of tear stability is the core mechanism and the initial cause of dry eye <sup>16</sup>. Tear film rupture caused by the decrease of tear film stability is the main cause of aberrations. The increase of aberrations can eventually lead to the decline of visual quality and the fluctuation of visual acuity <sup>17, 18</sup>.

**BN structure**

The main task is to find a model information that can make the best response. But the search process is NP hard. Now we give a clear formula, that is, f(m) formula represents the whole search space composed of BNM. In May, we saw an exponential growth of BN and m <sup>19,20</sup>. This paper focuses on two algorithms: constraint based method, point based method and hybrid algorithm:

$$f(m) = \sum_{i=1}^m (-1)^{i+1} \frac{m!}{i!(m-i)!} 2^{i(n-1)} \quad (2)$$

If P = 2, then M (B, c) is called relative euclid distance:

$$M_E(B, C) = \sqrt{\frac{1}{n} \sum_{i=1}^n |B(f_i) - C(f_i)|} \quad (3)$$

Let n fuzzy sets on universe h, R (C, b) be some closeness degree of fuzzy sets C and B. If is I such that:

$$R(C, B_{i0}) = \max \{R(C, B_k)\} \quad (4)$$

For Bayesian scoring method, scoring method in K2 is one of the earliest Bayesian scoring methods, and its scoring function is as follows:

$$v = \frac{1}{MN} \sum_{a,b \in s} (a,b) \quad (5)$$

**Ultrastructure**

Ultrastructure can restore the compressed data to the original data as unchanged as possible. Therefore, the data to be saved is not only the compressed data, but also the description of the original data. Therefore, the MDL principle will minimize the

sum of the compressed data and the description of the original data. So we apply this idea to BN structure learning and get its score:

$$e^2 = E\{h(b) - y(b)\} \quad (6)$$

Where  $f(g)$  is the complexity of the network:

$$F(G) = \sum_{i=1}^n (r-1)q \quad (7)$$

$$F_{new}^a = F^a - \alpha \frac{\partial}{\partial c^a} J(h, c) \quad (8)$$

Firstly, the average value and variance of each pixel in the neighborhood of the original image are estimated:

$$score(BN) = F_{data} - F_N \quad (9)$$

### Meibomian Gland Dysfunction

Normal meibomian gland secretion of lipids is an important part of lacrimal gland lipid layer, meibomian gland secretion dysfunction is the main cause of dry eye tear evaporation. Because of its epithelial variation, the epithelium of meibomian duct thickens and hyperkeratoses soon after birth, which leads to meibomian gland dysfunction. As a kind of meibomian gland dysfunction, estrogen plays an important role in maintaining the structure and function of lacrimal passage. Androgen can maintain the stability by controlling the secretion of meibomir gland. Estrogen can regulate the expression of MMP-9 and MMP-2 in the urethra of ovariectomized rabbits, thus participating in the pathogenesis of dry eye. The relationship between

ovariectomy and ocular surface lesions is shown in Figure 2:

### Method of Cell Ssrs Algorithm

Some improved learning SS methods in cell observation include the improvement of the original 01ss algorithm to opt01s algorithm. Opt01ss algorithm is based on constraint condition test, and the problems such as ADR and CI test are dealt with specially, and satisfactory results are obtained. Opt01ss algorithm is summarized as follows

### Scoring criteria

In SSRs algorithm, BIC scoring function is used as the scoring criterion. For BN to be compared, BIC scoring function can be used to evaluate BN. The higher the score is, the fitting degree of data is:

$$H_i(f_0) = \max\{H_k(f_0)\} \quad (10)$$

### Random search operation is the best way

In the first operation, the three operations on the edge are randomly selected by the algorithm itself. In the second operation, the selection of nodes is also random, so it is not necessary to specify a specific operation definition:

$$M(B, C) = \left[ \frac{1}{n} \sum_{i=1}^n |B(f_i) - C(f_i)| \right]^{\frac{1}{r}} \quad (11)$$

R is a positive real number. Let  $m(B, c)$  be the relative Minkowski distance of fuzzy sets B and C. if  $r = 1$ , then we get the following result:

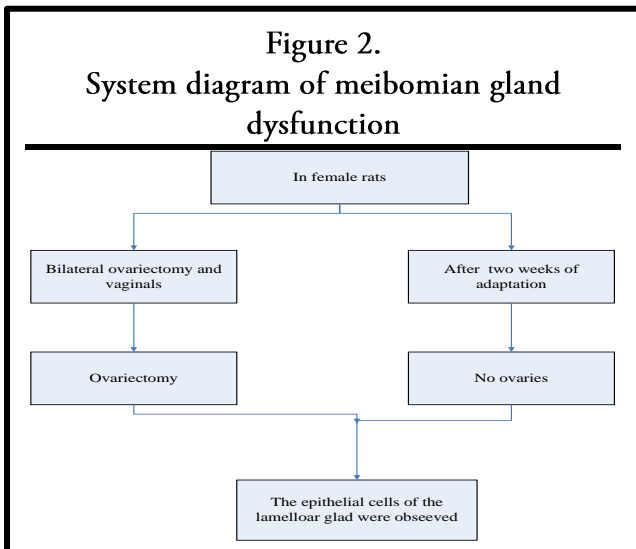
$$H(d) = \sum_{i=1}^n \sum_{j=1}^m \frac{1}{2} \log \left( \frac{M_i}{M_j} \right) \quad (12)$$

SS itself is an undirected graph, and the initial network in the algorithm requires DAG and multiple initial networks. Therefore, in the SSRs algorithm, G is denoted as:

$$G_{otsd} = g(\text{length}(G_{imit}) / 2) \quad (13)$$

Let n fuzzy sets on universe h, R (C, b) be some closeness degree of fuzzy sets C and B. If there is I such that:

$$P(d) = \frac{1}{2} \sum_{i=1}^n P_{ij} \quad (14)$$



## OVARIECTOMY ON THE ULTRASTRUCTURE OF MEIBOMIAN GLAND EPITHELIAL CELLS IN RATS

### Laboratory Animals

Healthy and clean adult female rats (experimental zoo of Suzhou University), aged 6-8 years old, weighing 25-30g, with natural circadian rhythm of 20-23 and humidity of 60% - 80%. To study eye diseases, the use of animals must comply with the "Regulations on the use of experimental animals" published by the science and Technology Committee; appropriate experimental animals were assigned to the experimental group and the control group of 30 cases. Ovariectomized rats were selected as experimental group and ovariectomized rats as control group.

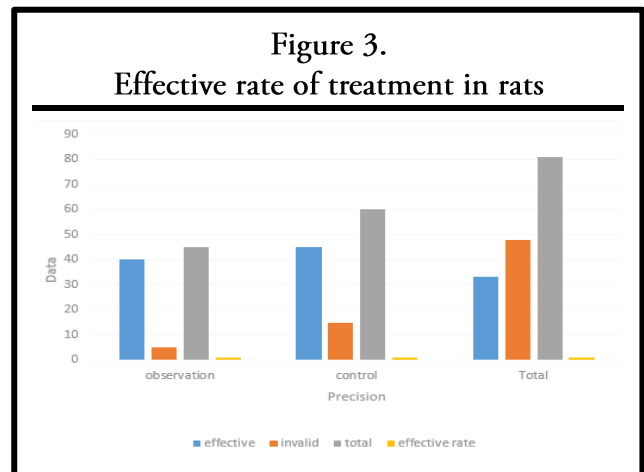
### Comparison of Ovariectomy in Rats

The changes of serum estradiol and testosterone concentrations in the two groups at different time after operation were 3 m. after ovariectomy, serum estradiol and testosterone began to decrease, and the difference was statistically significant in the control group. Compared with the operation, the serum estradiol and testosterone concentrations in ovariectomized rats continued to decrease after 6 months, and the difference was statistically significant compared with the control group. Table 1 shows that the difference was statistically significant:

**Table 1.**  
**Comparison of serum estradiol concentration in two groups at different time points**

Group	Preoperative	Postoperative 3M	Postoperative 6m
Control group	48	46	24
Experimental group	45	43	25
t	0.2	-8	-5
p	0.8	0.3	0.1

There was no significant difference in corneal fluorescein sodium staining points between the experimental group and the control group at 1 m and 3 m after operation. After that, the golden cornea fluorescein sodium changed color after 3M and 6m operation, which was higher than that of 1m after operation. The score of the control group was as shown in Table 2:



**Table 2.**  
**Comparison of serum testosterone concentration between two groups at different time points**

Group	Preoperative	Postoperative 1M	Postoperative 3m
Control group	3	2	1
Experimental group	4	3	2
t	0.3	-2	-2
p	0.8	0.4	0.2

### Effective Rate of Treatment in Rats

Estrogen receptor HL cells and epidermal cells are considered to be the main effector T cells in the development of dry eye disease. Although the mechanism of epithelial cells in dry eye disease is not fully understood, recent studies have shown that epithelial cells play an important role in the pathogenesis of dry eye disease. This finding suggests that the inflammatory mechanism of dry eye can be mediated not only by epithelial cells, but also by epithelial cells. In the pathogenesis of dry eye disease, under the action of APC, the activities of CD4 + THL cells secreting IFN -  $\gamma$  and CD4 + epidermal cells secreting IL-17 increase. At the same time, dysfunctional regulatory T cells make effector T cells in lymphatic vessels migrate to the ocular surface under the action of inflammatory cytokines and vegf-a. The increased levels of IL-17 and IFN -  $\gamma$  in ocular surface lead to the decrease of goblet cell density and chronic inflammation of ocular surface. Studies have shown that CD4 + T cells (THL) secreting ifn-7 and CD4 + T cells (epidermis) secreting IL-17 participate in the immune



inflammatory response of rat model of dry eye disease. Transforming growth factor  $\beta$  has different roles in epithelial cells and epithelial cell differentiation. Transforming factor  $\beta$  and IL-6 contribute to epithelial 7 cell differentiation. After treatment, the effective rate of observation group and control group is statistically significant, and the curative effect of observation group is better than that of control group, such as as shown in Figure 3:

**Establishment of Ovariectomized Rat Model**

The rats in the experimental group were intraperitoneally injected with 3.6% chlorinated water (10ml / kg). The hair on the back of the rats was cut to expose the skin, and the aniline iodine skin was disinfected. a joint on both sides of the 12 ribs, 1-1.5 cm in the posterior middle and outer spine. A long incision was made to cut the skin, separate the muscle, open the abdominal wall, penetrate the abdominal cavity, open and slightly separate the fat, expose the ovary, sew the lower door of the ovary, remove the ovary, and suture the wound level. In group D, the ovary was found, but not taken out, and then the incision layer was sutured. SPSS17.0 statistical software was used for statistical processing, and the measured data were consistent with the normal distribution, and the mean standard deviation was used to describe the differences of the indexes before and after treatment was described. T test was used to test the correlation between non normal distribution and parameter level test.

**Adenoimmunosuppression in Lymphoma**

Cyclosporine A is an effective immunosuppressant, which is mainly used in rejection after heart, liver and kidney transplantation. It can be used in patients with adrenocortical hormone and immune disorders. In recent years, topical cyclosporine A can effectively treat MGD and dry eye caused by excessive evaporation caused by MGD. Cyclosporine A can inhibit the immune response mediated by T cells, especially prevent the apoptosis of ocular surface cells, so as to achieve an effective anti-inflammatory formula:

$$A = -\log\left(\frac{R(f, \lambda)}{R_0(f, \lambda)}\right) \quad (15)$$

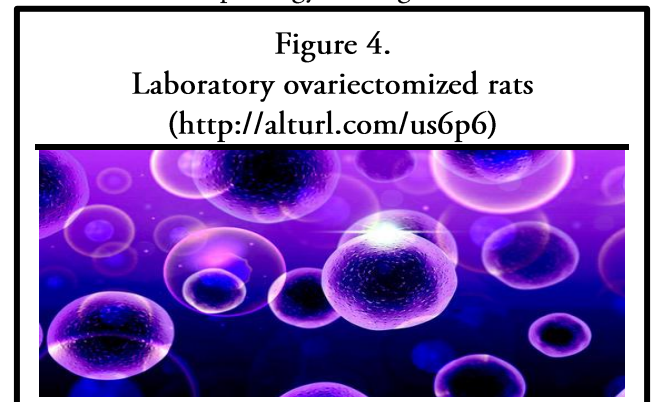
**OVARIECTOMY ON MEIBOMIAN GLAND IN RATS**

**Rat Blood Weight by Radioimmunoassay**

The experimental observation of the three groups of rats before intervention can see that there is no obvious change in the three groups of rats. After 6 months of intervention, the BMD of OVX group was significantly lower than that of the apparent group. The BMD of the sham group was significantly lower than that of the OVX group, but there was no significant difference between the sham group and the apparent group. The whole blood was extracted by vacuum blood collection and blood coagulation. After centrifugation, the serum was extracted with micro sampler and stored in refrigerator. The levels of estradiol and testosterone were detected by radioimmunoassay, as shown in Table 3:

Group	OVX	Sham
<b>Number of cases</b>	4	4
<b>Weight before intervention</b>	245	150
<b>Weight after intervention</b>	430	410
<b>BMD before intervention</b>	0.125	0.145
<b>BMD after intervention</b>	0.156	0.155

Table 3 shows that there is no significant difference in body weight among the three groups. After one month of intervention, the body weight of rats in each group increased significantly, especially in the ovariectomized group. Vaginal washing cell imaging model: one week after operation, the ovaries were taken, once a day, and the vagina was washed with normal saline. Vaginal washing cells and methylene blue staining were carried out for 6 consecutive days. In order to successfully remove the ovaries, the morphology of vaginal exfoliated cells



should be examined under the microscope. The procedure is the same as above, but after the ovaries are found, only the same weight of adipose tissue is removed, and then the main enzymes are produced layer by layer. As shown in Figure 4:

Figure 4 results after ovariectomy, the amount of tears in the study group began to decrease, and the difference was statistically significant compared with the control group, and the difference was statistically significant compared with the control group. changes of estrogen in rats. If the vaginal mucosa of the rats all remained in the oesophageal phase or pre oestrus, a large number of neutrophils and a small number of epithelial cells were occasionally seen, and no keratinocytes increased or dissolved, the ovariectomy was successful.

### Mgd Analysis

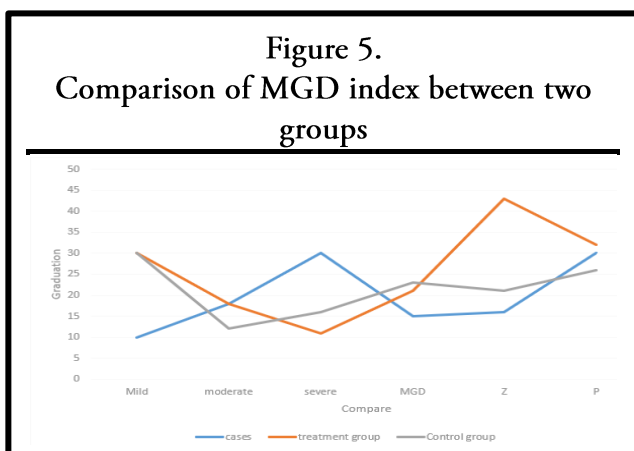
MGD is closely related to infection. The concentration of inflammatory factors such as interleukin in the tears of MGD patients increased. The changes of inflammatory cytokines lead to excessive keratosis of meibomian duct epithelium and abnormal secretion of eyelid ester, which leads to instability of lacrimal passage and complete orientation of eyes. Other studies have shown that: during the treatment of MGD, the average level of cytokines in the tears of patients with MGD can be reduced while the average level of cytokines in the tears of patients with MGD is normal, and the eyelid cleaning and hot compress of patients with moderate

bacteria and ocular pathogenic bacteria; dexamethasone is a powerful anti-inflammatory drug, which can prevent inflammatory reaction caused by various factors, and local glucocorticoid may act faster through MGD: it is suitable for two to four weeks of short-term shock treatment and regular monitoring of intraocular pressure, because of possible complications, so it is in the eye high voltage avoid long-term use, as shown in Figure 5:

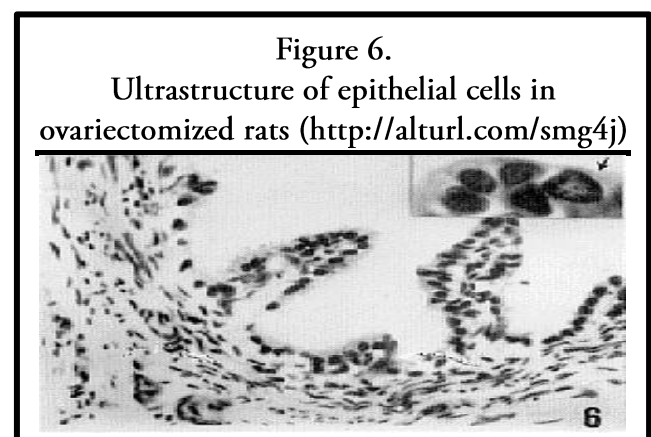
It can be seen from Figure 5 that because of the different mechanisms of action of these treatments, continuous treatment can be adopted, and the accumulation of side effects caused by long-term application of the same drug can be reduced. Tamoxifen and toremifene directly act on the digestion of estrogen receptor cells. After dilution and counting, they are seeded into the special culture plate with 8000 cells / well, and each cell has 5 repeat wells. When the cell adheres to the wall and grows normally, and the cell density is about 80%, the experiment is carried out. Before testing on the computer, it is necessary to change the solution of the cells, wash them twice with the freshly prepared assay medium, and finally add 500 μ l of assay medium into each well, and send them to the carbon dioxide free incubator for cultivation and testing on the computer.

### Rna Reverse Transcription Analysis

Meibomian gland dysfunction is characterized by meibomian duct obstruction or abnormal meibomian gland secretion. It is a kind of chronic,



and severe MGD can achieve good results. result. At the same time, the study concluded that tobramycin / dexamethasone eye cream is effective on common



diffuse and nonspecific thyroid inflammation, which usually leads to lacrimal gland instability, eye irritation and inflammatory reaction, leading to

inflammation and damage of the ocular surface. The early manifestation of MGD is mainly the uplift of meibomian gland opening. Reverse transcription is carried out according to the instructions of reverse transcription Kit. The reaction system is 30U, as shown in Table 4:

Reagent	volume
R nose free dH2O	5
5×rimescript buffer	6
Primescript RT enzyme mix	1.5
Oligo dt primer (50uM)	2
Random 6 mers (100uM)	4
Total RNA(100ng/ul)	14

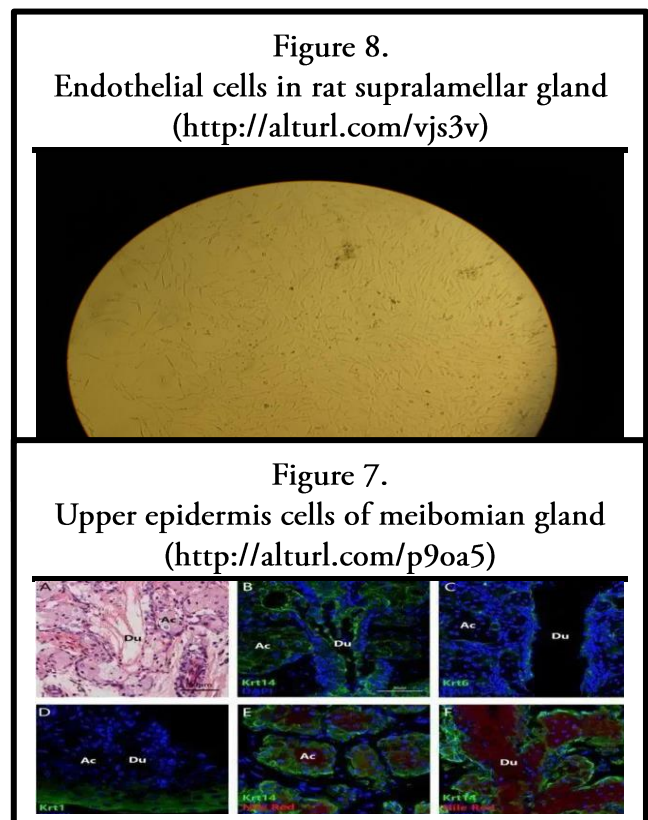
It can be seen from table 4 that RNA purity detection: take 2.4ul RNA stock solution, add 600ul buffer solution, dilute, mix and send for inspection, respectively determine the OD value of 260nm and 280nm samples, and determine the RNA concentration of each group. Cyclosporine A can significantly improve the eye discomfort of patients with dry eye, but cyclosporine A is not allowed in women with eye infection, pregnancy and diabetes. Breast feeding and sex hormone therapy have been proved to be a potential treatment for MGD. Showed that estrogen receptor was evenly distributed in meibomian gland and involved in the regulation of lacrimal gland lipid secretion. There was no significant difference in the incidence of Er between male and female meibomian glands. Participate in meibomian gland lipid secretion and lacrimal sex hormones. Local application can reconstruct the tear lipid layer, improve the epithelial vasculitis, and be used as an adjuvant treatment for MGD. As shown in Figure 6:

The evaluation of follicle quality and the selection of high-quality embryos are the key to improve the success rate of IVF-ET, which has become a hot and difficult point in the field of reproductive health. However, COH, the key link in IVF-ET technology, damages the quality of oocytes and embryos to a certain extent, thus affecting the final clinical outcome of IVF-ET. Therefore, if some measures can be used in the IVF-ET process for clinical intervention, in order to reduce the adverse effects of artificial over physiological dose of hormone on the quality and development potential of oocytes and

follicles in the process of COH, it will improve the quality and development potential of embryos in the IVF-ET cycle according to this experiment, we get the results in Table 5:

Experimental steps	n
Exclusion	33
Reviews	43
Case reports	12
Letters	54
Clinical trials	67

After a week, it was roasted in the zoo for 8 hours, and was carried out in the operation room of small animals, and 10% chloroform anesthesia was injected intraperitoneally. When anesthesia begins, hair is pulled out and towels are sterilized, take 1/3 incision under abdomen, about 1cm long. Find the



uterus with "Y" type, gently pull one side, find one side of the palace angle, and see a pink mulberry like tissue, namely ovary, free ovary and fallopian tube. After ligation of silk thread, it is near the end of the corner of the fallopian tube, and the ovaries are removed. The ovaries and the remnant ends of both angles were observed to ensure complete resection. Put the uterus back to its original place and sew it up. After the rats were re heated, they were put back



into the cage after they were fully awake. We observed that their cells were as shown in Figure 7:

In order to evaluate the effect of bilateral ovariectomy on glucose tolerance in rats and the effect of E2 and DHEA on glucose tolerance in ovariectomized rats, OGTT was detected in rats after 12 weeks of intragastric administration. The blood glucose values of tail vein at 0, 30, 60 and 120 min after intragastric administration were detected respectively. There was significant difference in the area under OGTT curve after 12 weeks of E2 and DHEA treatment. Compared with sham group, the area under the curve of OVX group increased significantly. Compared with OVX group and OVX + DHEA group, the area under the curve of OVX + DHEA also decreased significantly. The morphology and types of vaginal incubated cells persist in vaginal mucus. The results of vaginal mucosa showed that the rats lost the normal estrogen cycle activity, indicating that the ovaries were removed. After ovariectomy, the concentration of estrogen in rats decreased significantly, the uterus lost the function of estrogen and gradually atrophied. After the rats were killed, the ovaries of the rats were carefully searched, the uterus was isolated, the morphology of the uterus was observed, and the wet weight of the uterus was weighed. If the wet weight of the uterus was significantly reduced, it was clear that the cells observed by the operation were successfully implemented, as shown in Figure 8:

After replacement with dehydroepiandrosterone, the wet weight of uterus did not increase significantly. It can be speculated that dehydroepiandrosterone alone may not have effect on endometrium. Unlike estrogen, DHEA may not increase the incidence rate of endometrial cancer, which requires further experimental validation. To simulate the hormone fluctuation level in perimenopausal women, and then give exogenous estrogen and dehydroepiandrosterone supplement, we can systematically understand the effects of estrogen and dehydroepiandrosterone on body lipid metabolism, glucose metabolism, depression and anxiety like behavior, and seek support for estrogen and dehydroepiandrosterone replacement therapy.

## CONCLUSION

In this paper, the experimental investigation method was used to select the non ovariectomized rats and ovariectomized rats were divided into two groups, to observe the ultrastructure of meibomian epithelial cells in ovariectomized rats, and to explore the effect of ovariectomy on meibomian gland. Results the main clinical manifestations of MGD company were abnormal thyroid secretion, meibomian duct obstruction and meibomian adenitis. So how to effectively treat this disease has become a hot topic and prominent problem in recent years. Through consulting a large number of Ophthalmology related ancient books and modern literature, summarizing the clinical experience of the tutor and the MGD of Ophthalmology Related to the observation and research of dry eye patients, it is found that in all patients with dry eye, the syndrome of spleen deficiency, damp heat and toxin stagnation accounts for the largest proportion, and in the early long-term clinical practice, through the use of invigorating the spleen, removing dampness, clearing heat and detoxification of traditional Chinese medicine, it has a good effect on the treatment of this disease.

## REFERENCES

1. Qi, S., & Zheng, H. (2017) "Combined Effects of Phytoestrogen Genistein and Silicon on Ovariectomy-Induced Bone Loss in Rat", *Biological Trace Element Research*, 177(2), pp.1-7.
2. Kim, M. H., Jung, K., & Nam, K. H. (2016) "Salvia Plebeia R.Br. Inhibits Signal Transduction of IL-6 and Prevents Ovariectomy-induced Bone Loss by Suppressing Osteoclastogenesis", *Archives of Pharmacal Research*, 39(12), pp.1-11.
3. Mi, Y., Jung, J., Wan, K., Ki, Y., & Kim, S. (2016) "A  $\beta$ -glucan from *Aureobasidium Pullulans* SM-2001, Mitigates Ovariectomy-induced Osteoporosis in Rats", *Experimental and Therapeutic Medicine*, 12(3), pp.1251-1262.
4. Bellini, L., Mollo, A., & Contiero, B. (2017) "Intraoperative End-tidal Concentration of Isoflurane in Cats Undergoing Ovariectomy that Received Tramadol, Buprenorphine or a Combination of Both", *Journal of Feline Medicine & Surgery*, 19(2), pp.110-116.
5. Wei, M., Gan, L., Sha, X., Lu, H. Y., Jiang, Y. H., Lei, X. Y., Xu, C. M., Ruan, B. J., Wang, L., & Lu, Z. F. (2016) "Mitochondria Related Peptide MOTS-c Suppresses Ovariectomy-induced Bone Loss Via AMPK Activation", *Biochemical and Biophysical Research Communications*, 476(4), pp.412-419.
6. Qu, N., Zhou, X. Y., & Han, L. (2016) "Combination of PPT with LiCl Treatment Prevented Bilateral

- Ovariectomy-induced Hippocampal-dependent Cognition Deficit in Rats”, *Molecular Neurobiology*, 53(2), pp.894-904.
7. Wang, Y. G., Jiang, L. B., & Gou, B. (2017) “Protective Effect of Vanillic Acid on Ovariectomy-induced Osteoporosis in Rats”, *African Journal of Traditional Complementary & Alternative Medicines*, 14(4), pp.31-38.
  8. Hadi, Y., Pouran, K., & Alireza, A. (2017) “Therapeutic Potential of Genistein in Ovariectomy-induced Pancreatic Injury in Diabetic Rats: The Regulation of MAPK Pathway and Apoptosis”, *Iranian Journal of Basic Medical Sciences*, 20(9), pp.1009-1015.
  9. Picazo, O., Espinosa-Raya, J., & Briones-Aranda, A. (2016) “Ovariectomy Increases the Age-induced Hyperphosphorylation of Tau at Hippocampal CA1”, *Cognitive Processing*, 17(4), pp.1-7.
  10. Haskell, S. E., Peotta, V., & Reinking, B. E. (2016) “Oral Estrogen Reverses Ovariectomy-induced Morning Surge Hypertension in Growth Restricted Mice”, *Clinical Ence*, 130(8), pp.641-6.
  11. Ivić, V. B., & Labak, S. (2016) “Ovariectomy and Chronic Stress Lead toward Leptin Resistance in the Satiety Centers and Insulin Resistance in the Hippocampus of Sprague-dawley Rats”, *Croatian Medical Journal*, 57(2), pp.194-206.
  12. Gho, D., Sra, J., Nickoli, M., & Hashmi S. (2016) “Ovariectomy-induced Osteoporosis Does Not Impact Fusion Rates in a Recombinant Human Bone Morphogenetic Protein-2 – Dependent Rat Posterolateral Arthrodesis Model”, *Global Spine Journal*, 06(01), pp.060-068.
  13. Ma, Y., Chu, J., & Ma, J. (2017) “Sanguinarine Protects Against Ovariectomy-induced Osteoporosis in Mice”, *Molecular Medicine Reports*, 16(1), pp.288-294.
  14. Cheon, S. (2017) “Hippocampus-dependent Task Improves the Cognitive Function after Ovariectomy in Rats”, *Osong Public Health Res Perspect*, 8(3), pp.227-234.
  15. Akopian, A. N., Green, D. P., & Patil, M. J. (2016) “Influence of Hypophysectomy, Ovariectomy and Gonadectomy on Postoperative Hypersensitivity in Rats”, *Global Anesthesia & Perioperative Medicine*, 2(2), pp.171-175.
  16. Tallant, A., Ambros, B., & Freire, C. (2016) “Comparison of Intraoperative and Postoperative Pain during Canine Ovariohysterectomy and Ovariectomy”, *Canadian Veterinary Journal-revue Veterinaire Canadienne*, 57(7), pp.741-746.
  17. Duarte, A. F., Akaishi, P. M. S., GA, D. M. S., Chodraui-Filho, M. C. A., Toscano, W. A. S., & Cruz, A. A. V. (2017) “Lacrimal Gland Involvement in Blepharophimosis-ptosis-epicanthus Inversus Syndrome”, *Ophthalmology*, 124(3), pp.399-406.
  18. Chinmayee, J. T., Ramesh, T. K., & Eswaran, V. (2016) “Outcome of Levator Reattachment Surgery for Blepharoptosis in Blepharochalasis”, *Journal of Evidence Based Medicine and Healthcare*, 3(69), pp.3743-3747.
  19. Dutton, L. R., Hoare, O. P., & Mccorry, A. (2019) “Fibroblast-derived Gremlin1 Localises to Epithelial Cells at the Base of the Intestinal Crypt”, *Oncotarget*, 10(45), pp.4630-4639.
  20. Tan, J. J., Narang, S., & Purewal, B. (2019) “Extranodal Rosai-dorfman Disease of the Orbit: Clinical Features of 8 Cases”, *Ophthal Plast Reconstr Surg*, 32(6), pp.458-461.