

Prevention of Postoperative Pancreatic Fistula

Ahmed Magdy Mohamed Abd Elfattah¹, Mansour Mohamed Morsy¹, Ahmed Shoukry Hafez², Osama Abd Elaziz Mohamed¹, Ramadan Mahmoud Ali¹

1 General Surgery Department, Faculty of Medicine - Zagazig University, Egypt

2 Consultant of Surgical Oncology & Laparoscopic Surgery, Alsalam Oncology Center

Corresponding author: Ahmed Magdy Mohamed Abd Elfattah

E-mail: moodymagdy77@gmail.com

Conflict of interest: None declared.

Funding: No funding sources

Abstract

After pancreatic surgery, the development of postoperative pancreatic fistula (POPF) is a serious concern. POPF involves the leakage of pancreatic fluids from the surgical site, which can lead to complications and even death. Preventing POPF is essential for enhancing patient recovery and lessening the impact on healthcare resources. To prevent complications following PD, various techniques of managing the pancreatic remnant have been proposed. These range from pancreatic ductal occlusion to pancreaticoenterostomy with jejunum or stomach.

Keywords: Postoperative Pancreatic Fistula

TobRegul Sci.™ 2023; 9(1): 8338 - 8346

DOI: doi.org/10.18001/TRS.9.1.588

Introduction

To prevent complications following PD, various techniques of managing the pancreatic remnant have been proposed. These range from pancreatic ductal occlusion to pancreaticoenterostomy with jejunum or stomach [1].

(1) Pancreatic Duct Occlusion

When PD was initially performed, the most common management of the residual pancreas was ligation of the main pancreatic duct and suturing of the pancreatic stump [2]. It is an easier technique, shorter in time and some Authors argue that a PF from the oversewn pancreatic stump is less dangerous than one from PJ because there is no defect in the small bowel and no enzymatic activation [3]. After transection of the pancreas, the main pancreatic duct is identified, and a fine purse string suture is made and then the pancreatic remnant can be oversewn with interrupted non absorbable sutures [1]. The pancreas transection with the closure of the duct can be made also with a linear stapler. The pancreatic stump is then closed with interrupted sutures to prevent secretion leaks from minor ducts [4].

Recently, several chemical substances have been proposed to achieve the duct occlusion, such as Ethibloc, Neoprene glue, Fibrin glue and Cianoacrilate [3]. It has been demonstrated that

pancreatic juice leakage at the pancreatic stump occurred easily following ligation of the main pancreatic duct, followed by gradual atrophy of the pancreas, complete loss of endocrine and exocrine function, postoperative diabetes, and reduced quality of life [5]. Even if endocrine function may be preserved and life-long enzymatic substitution can palliate complete exocrine insufficiency this technique was rarely used because of the risk of postoperative pancreatitis, permanent exocrine and endocrine insufficiency, the fear of severe haemorrhagic complications. As a consequence, this method now is the least preferred and only reserved to selected cases such as friable stump with small pancreatic duct [6].

(2) Pancreaticojejunostomy (PJ)

Reconstruction methods between the pancreas and the small bowel include various forms ranging from end-to-side anastomosis, end-to-end anastomosis or pancreatic intussusception in the jejunum [5].

End-to-side PJ was first described by Cattell. After the excision of the specimen, the end of the jejunum is closed, and the jejunal loop is placed, with its mesenteric edge, in contact with the pancreatic sectional area, with a slight clockwise rotation [7]. The transected end of the pancreas can be anatomized with two variants: (1) direct anastomosis in a single plain, consisting of an anastomosis between the upper and the lower pancreatic edge and the longitudinal gap in the jejunum. (2) duct-to-mucosa anastomosis, which is the most frequently used especially when the duct is dilated (>3 mm) and the parenchyma is firm. A catheter can be inserted in the pancreatic duct to record the duct's diameter and to protect the anastomosis [8].

End-to-end PJ, in this method the pancreatic stump should be freed for several centimetres in preparation to invaginate it into the end of the jejunum [9]. Once the jejunum and the pancreas are prepared, a layer of interrupted suture is placed between the posterior pancreatic capsule and the seromuscular layer of the jejunum. The cut surface of the jejunum is sewed to the inner margin of the pancreas. An additional anterior layer of interrupted sutures is placed to pull the jejunal wall up over the pancreatic parenchyma for approximately 2 cm [10].

The basic types of PJ evolved subsequently to include invagination pancreaticojejunostomy, binding pancreaticojejunostomy and duct-to-mucosa pancreaticojejunostomy [5].

Invagination (Dunking) pancreaticojejunostomy (IPJ):

In 1941, IPJ was first used clinically for the management of pancreatic stump following PD [11]. IPJ is performed by invagination of the pancreatic stump into the intestine in either an end-to-end or an end-to-side manner. For the convenience of performance, no requirement for identification of the main pancreatic duct [11]. IPJ has been considered as the conventional and classic anastomosis method from the origin of PD and is the most common type of PJ used nowadays [9].

The incidence of postoperative complications has also been regarded as standard for evaluation of different techniques. As reported in many publications, the POPF rate varies greatly in different reports in patients underwent IPJ because of variations in definitions used for POPF [1]. Different pancreaticojejunal invagination techniques have been proposed: including the inverting IPJ, the dentate inter-locking PJ, and the double-layer continuous IPJ. Among these proposals of PJ, several

modified techniques have been reported to give very good results [12]. One is the “Transpancreatic U-sutures IPJ” developed by Chen X P et al. which presents a new technique of the end-to-end IPJ with two to three transpancreatic U-sutures. The POPF caused by needle penetrates was decreased through reducing the suture in pancreatic parenchyma and ductules. This Transpancreatic U-sutures IPJ was widely considered as the first proponent for the principle of superabundant suture in pancreas leading to excess POPF [13]. Similarly newly developed “pulling IPJ” by Chen and his colleagues in 2008 showed less incidence of POPF.

Recently, Nakanishi Y et al. developed the “Four sutures IPJ” with a 0% grade B or C pancreatic fistula rate in 15 consecutive patients who underwent PD [14].

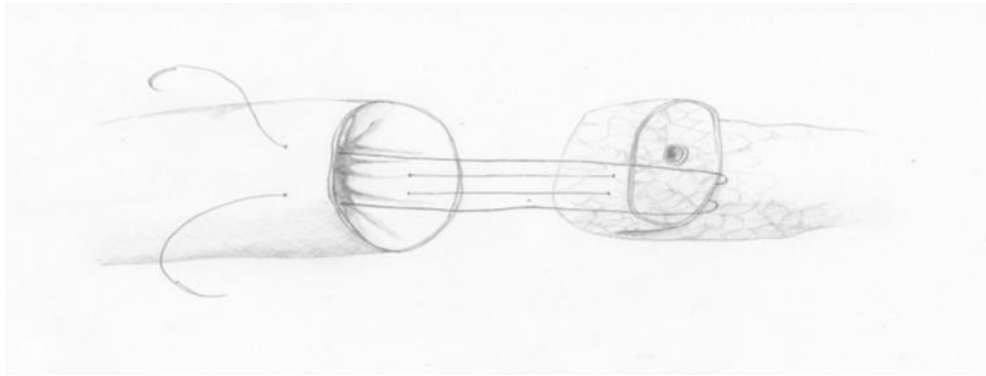


Figure (1): Chen’s U-suture technique [13].

Yang et al. presented another modification, called „the Colonial Wig” due to its appearance. First, the pancreas is invaginated by U-sutures into the antimesenteric side of the jejunum. Then, the closed end of the jejunum and its deferent loop are sutured by single interrupted stitches to the pancreatic trunk, thus securing the upper and lower corner of the anastomosis. The finishing touch is a sealing layer of interrupted sutures between the pancreatic capsule and the intestinal wall [15].

Binding pancreaticojejunostomy (BPJ):

Peng et al. proposed that pancreatic fistula starts at a point where a needle inadvertently penetrates a pancreatic ductule or a suture lacerates the fragile pancreatic parenchyma on suturing or tying a knot. The resultant minor leak in pancreatic juice gradually leads to gross leakage as a consequence of autodigestion around the anastomosis. Based on this hypothesis, Peng et al. described a BPJ technique [16].

The technique includes three modifications: (1) the jejunum is everted on itself to make a first anastomosis between the jejunal mucosa and the pancreas; (2) to improve cohesion between the pancreas and jejunum, the jejunal mucosa covering the pancreas along 2–3 cm is initially destroyed by chemical or thermal means to create an adhesion zone; and (3) a ligature is applied around the covered area after the procedure when the jejunum is properly arranged on the pancreas [16].

However, this binding technique was limitedly used due to certain points: First, the tension of binding is hard to control. Too tight binding may cause necrosis, resulting in severe POPF, while too loose binding may not impede pancreatic juice leakage [17]. Second, the jejunal mucosa is difficult to suture. If the mucosa is destroyed, vascularization of anastomosis is compromised; if the mucosa is completely intact the pancreatic stump may be exposed to pancreatic juice, which

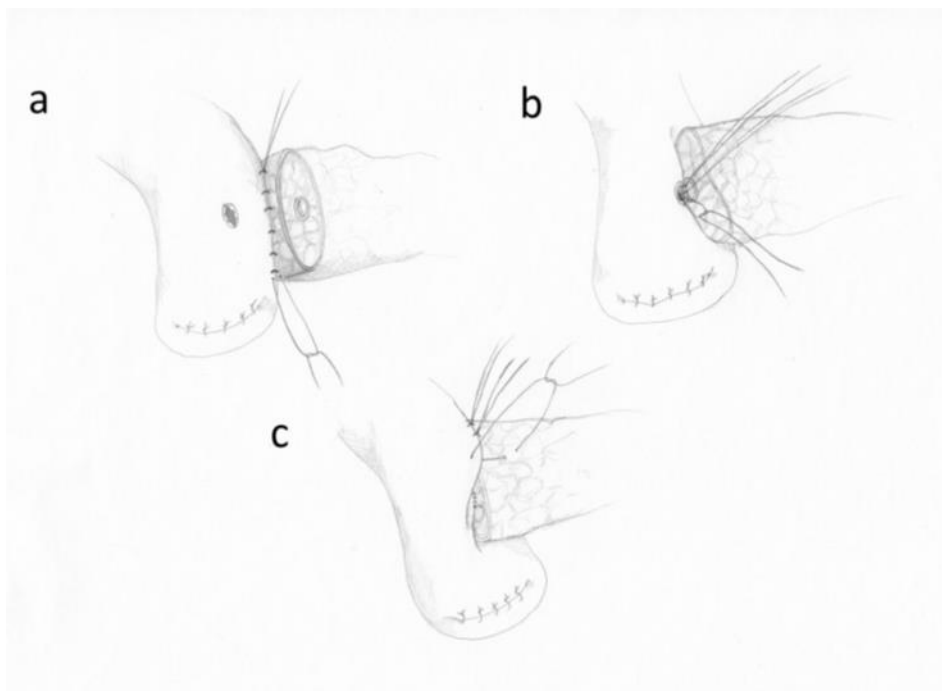
may lead to bleeding at the anastomotic site [4]. Third, BPJ was originally performed in an end-to-end manner, so this technique may not be completed when the intestine is too small or the pancreatic stump is too large to invaginate the pancreatic stump into the jejunum. Therefore, further well-designed, large-volume studies are required to accumulate evidence to draw conclusion [18].

Duct-to-mucosa pancreaticojejunostomy (DmPJ):

DmPJ was first performed by Varco in 1945. The classical duct-to-mucosa technique can be considered to be a two-layer anastomotic technique, with the inner layer consisting of suturing of Wirsung's duct to jejunal mucosa. DmPJ allows for tight adhesion between the pancreatic stump and intestinal wall, enabling rapid and close adherence due to absence of effusion, and rapid anastomotic patency and exocrine function [19]. In addition, DmPJ does not take into account the size of the residual pancreas and eversion of intestinal mucosa is not required [19].

Due to these benefits, DmPJ is considered to be safe with a low incidence of pancreatic leak and has been used for a long time. However, dead space may exist between the pancreatic stump and jejunal wall, resulting in retention of pancreatic juice from the accessory or tiny pancreatic ducts. Furthermore, if the Wirsung's duct has a small diameter, DmPJ is difficult and the anastomosis is likely to obstruct [9].

Duct-to-mucosa and invagination are two classical PJ techniques. Many studies have compared these two techniques, but the results are difficult to interpret because these studies involved different definitions of pancreatic fistula, heterogeneous methodological trial designs, varying surgical skills and various combinations of other auxiliary treatments [9].



Figure(2): The duct to-mucosa anastomosis.

a-The posterior external wall. b-The posterior interior wall. c-The anterior external wall.
[13].

(3) Isolated loop pancreaticojejunostomy (ILPJ)

Isolated Roux loop for drainage of pancreatic stump was initially introduced by Machado et al. in 1976. Currently, there are two refinements. One is to separate the PJ and choledochojejunostomy from gastrojejunostomy into two routes, thereby decreasing the risk of bile reflux gastritis, retrograde cholangitis, and dumping syndrome. The second and the mainstream is to separate the PJ from the hepaticojejunostomy and gastrojejunostomy by an isolated Roux loop reconstruction [20].

Proponents of this technique believe that diversion of bile away from the PJ minimizes pancreatic enzyme activation and reduces the risk of pancreatic fistula [21]. Another argument in favor of using a Roux loop in PJ relies on the belief that if a pancreatic fistula forms, it will be a pure pancreatic fistula and these fistulae cause less complication when compared with a complex pancreatic fistula in which bile activates pancreatic juice with more morbidity and mortality [22].

In view of these expected advantages, many centers started using an isolated Roux loop of jejunum for PJ, with several cohort studies reporting a reduction in the incidence of pancreatic fistula and its related mortality [23]. However, other studies showed that this technique failed to demonstrate any significant reduction of pancreatic anastomosis leakage. The data showed that complication rates; POPF rates, grade and duration of spontaneous closure; morbidity and mortality were of the same in the ILPJ group when compared to CPJ [23].

The explanation given was healing of pancreaticoenteric anastomosis is dependent on many factors and diversion of bile is only one of them. Even activation of leaking pancreatic juice is not solely dependent on the presence of bile: intestinal juices can also activate pancreatic secretions [24].

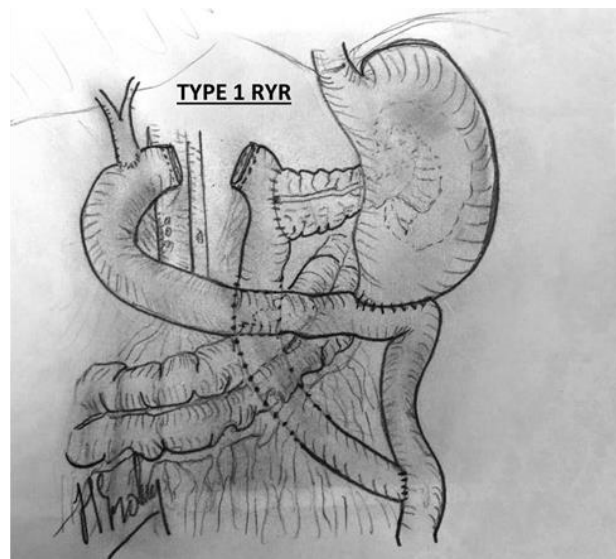


Figure (3): Isolated Roux en Y loop pancreaticojejunostomy [25].

(4) Pancreaticogastrostomy (PG)

In the classic PG, proposed by Waugh & Clagett in 1946, a duct-to-mucosa anastomosis is performed. The pancreatic stump is sutured to the seromuscular layer of the gastric wall, while the

pancreatic duct is full-thickness sutured to the stomach with or without a positioning of pancreatic stent. Suturing can be performed from the posterior gastric surface or from the inside of the gastric cavity through an anterior gastrostomy [26]. Alternative procedures include a binding or purse string suture around the anastomosis in the gastric wall, with complete stitches traversing the anterior and posterior surface of the pancreatic stump associated with a duct to-mucosa anastomosis or a “gastric partition” where the PG is performed. An aspirating nasogastric tube is always recommended [23].

PG has gained favor in recent years as a possible means of reducing the incidence of pancreatic fistula. Proponents have noticed several potential advantages. These include that pancreatic enzymes are inactivated by gastric acid environment; moreover, the enzymes remain in inactive form as the stomach does not contain enterokinase, resulting in a lack of activation of proteolytic enzymes [5].

Furthermore, the proximity of the pancreas to the posterior stomach wall allows potentially less tension on the anastomosis. The excellent blood supply to the stomach wall is favorable to anastomotic healing and the thickness of the stomach holds sutures well [27]. Also, PG reduces the number of anastomosis in a single jejunal loop potentially decreasing the kinking risk. Moreover, in case of haemorrhage or leakage, the site is easier to manage with gastroscopy instead of reoperation [28].

An important advantage of PG is that the anastomosis is located at a certain distance away from the major blood vessels which are skeletonized during the resection phase and then are less prone to be damaged in case of PF. PG also gives the advantage of draining an eventual PF by the use of a nasogastric tube avoiding potentially invasive procedures [29].

However, some potential disadvantages of PG have been recognized, including increasing evidence of delayed gastric emptying, pancreatic duct obstruction due to overgrowth of the gastric mucosa and risk of haemorrhage due to acid erosion of blood vessels [30].

Other Surgical Technical Approaches:

(1) Role of Magnification in Pancreatic Anastomosis

Operating loupes have been used by many experts to allow precise reconstruction of duct to mucosa pancreaticojejunostomy. Technical errors that may occur during anastomosis include crossing of the sutures, including both sides of the pancreatic duct while passing the sutures, taking unequal or inadequate amounts of pancreatic duct and jejunal mucosa and incorrect knot placement resulting in air knots. All these events can be avoided by using magnification [31].

(2) Blood Supply Based Technique of PD

This technique is based on the concept that the neck of the pancreas is a vascular watershed area and more liable for ischemia which may affect pancreaticojejunal anastomosis. According to this concept Strasberg et al. evaluated the blood supply at the cut surface of the pancreas and if necessary the pancreas is cut back 1.5 cm to 2 cm to improve the blood supply. Thereafter, the anastomosis is performed meticulously under magnification [32].

(3) Total Pancreatectomy

The rationale for total pancreatectomy is that it allows a more extensive lymphadenectomy, avoids the risk of a leak from the pancreatic anastomosis and decreases the chance of a positive resection margin [4]. However, total pancreatectomy is associated with obligatory diabetes mellitus, decreased immunity because of splenectomy, and loss of pancreatic exocrine function. Hence, it is no surprise that most studies have reported either worse survival or no survival difference between total pancreatectomy and standard PD [33]. The indication for total pancreatectomy would include serial positive resection margin obtained on frozen section, a very soft pancreas with a potentially increased risk of PF and in patients with documented family history of multicentric pancreatic cancer [33].

(4) Pancreatic Duct Stenting

One of the technical modifications in pancreatocenteric anastomosis is the use of a transanastomotic stent for internal and external drainage of pancreatic secretion [1]. The potential advantages of a pancreatic stent include diversion of pancreatic secretion from the anastomosis and facilitation for more precise placement of sutures during the anastomosis, thus protecting the pancreatic duct from suture injury and reducing the risk of iatrogenic pancreatic duct occlusion (Pessaux et al., 2011) [2].

However, complications such as obstruction of the stent leading to pancreatic fistula and migration of the stent are drawbacks with transanastomotic stenting. An external stent has a theoretical advantage of more complete diversion of pancreatic secretion away from the pancreatocojejunal anastomosis and prevents the activation of pancreatic enzyme by bile [1].

Role of somatostatin use:

Somatostatin is a potent inhibitor of endocrine and exocrine functions. The synthetic peptide octreotide contains the same amino acid sequences essential to the activity of somatostatin, while conferring resistance to enzyme degradation, resulting in a long-acting stable analogue suitable for subcutaneous administration. The rationale of its use following PD is that by decreasing the volume of pancreatic secretion, the pancreatic fistula rate would be decreased because of which the pancreatocenteric anastomosis would heal better [34].

Adverse effects of somatostatin and its analogues include nausea, flatulence, diarrhea, steatorrhea, pain at the injection site, and abdominal discomfort [35]. The prophylactic use of perioperative somatostatin and its analogues to prevent POPF remains controversial. It does not result in a reduction of mortality. However, the efficacy of prophylactic octreotide is reported to be improved, by selective administration in the setting of high-risk glands, including patients with either soft glands or small pancreatic duct, in those harbouring ampullary, duodenal cystic or islet lesions, or in case where intraoperative blood loss is excessive [35].

No Conflict of interest.

References:

1. McMillan T, Malleo G, Bassi C, et al. Defining the practice of pancreatoduodenectomy around the world. *HPB (Oxford)*. 2015;17(12):1145-1154.

2. Unno M. Randomized clinical trial of external stent drainage of the pancreatic duct to reduce postoperative pancreatic fistula after pancreaticojejunostomy. *Br J Surg.* 2012;99(4): 524-531.
3. Cheng Y, Ye M, Xiong X, et al. Fibrin sealants for the prevention of postoperative pancreatic fistula following pancreatic surgery. *Cochrane Database Syst. Rev.* 2016;2, CD009621.
4. Machado O. Pancreatic Fistula after Pancreatectomy: Definitions, Risk Factors, Preventive Measures, and Management-Review Article. *International Journal of Surgical Oncology.* 2012;Volume 2012, Article ID 602478: 1-10.
5. Rezende M, Dutra S, Gestic A, et al. Pancreaticoduodenectomy: impact of the technique on operative outcomes and surgical mortality. *ABCD Arq Bras Cir Dig.* 2019;32(1): e1412.
6. Conzo G, Gambardella C, Tartaglia E, et al. Pancreatic fistula following pancreatoduodenectomy. Evaluation of different surgical approaches in the management of pancreatic stump:Literature review.*International Journal of Surgery.* 2015;21: 4-9.
7. Grobmyer SR, Kooby D, Blumgart LH, Hochwald SN. Novel pancreaticojejunostomy with a low rate of anastomotic failure-related complications. *J Am Coll Surg.* 2010;210(1):54–59.
8. Hashimoto D, Hirota M, Yagi Y, et al. End-to-side pancreaticojejunostomy without stitches in the pancreatic stump. *Surg Today.* 2013;43(7): 821–824.
9. Hua J, He Z, Qian D, et al. Duct to mucosa versus invagination pancreaticojejunostomy following pancreaticoduodenectomy: a systematic review and meta-analysis. *Journal of Gastrointestinal Surgery.* 2015;19(10): 1900–1909.
10. Chen Y, Ke N, Tan C, et al. Continuous versus interrupted suture techniques of pancreaticojejunostomy after pancreaticoduodenectomy. *J Surg Res.* 2015;193(2): 590–597.
11. Kusnierz K, Mrowiec S, and Lampe P. A comparison of two invagination techniques for pancreatojejunostomy after pancreatoduodenectomy. *Gastroenterol Res Pract.* 2015;894292.
12. Chen P, Huang Y, Lau Y, et al. Chen's U-Suture technique for end-to-end invaginated pancreaticojejunostomy following pancreaticoduodenectomy. *Ann Surg Oncol.* 2014;21: 4336–4341.
13. Olakowski M, Grudzińska E, Mrowiec S. Pancreaticojejunostomy:a review of modern techniques. *Langenbeck's Archives of Surgery.* 2020;405:13–22.
14. Nakanishi Y, Ohara M, Noguchi M, et al. New invagination procedure for pancreaticojejunostomy using only four sutures. *World J. Surg.* 2012;36 (4): 892-897.
15. Yang X, Aghajafari P, Goussous N, et al. The “Colonial Wig” pancreaticojejunostomy: zero leaks with a novel technique for reconstruction after pancreaticoduodenectomy. *Hepatobiliary Pancreat Dis Int.* 2017;16(5): 545–551.
16. Peng Y, Wang W, Li T, et al. Binding pancreaticojejunostomy: a safe and reliable anastomosis procedure, *HPB Oxf.* 2004;6(3): 154-160.
17. Kim M, Hong B, Shin Y, et al. Preliminary results of binding pancreaticojejunostomy. *Korean J Hepato-Biliary-Pancreatic Surg.* 2014;18(1): 21–25.
18. Casadei R, Ricci C, Silvestri S, et al. Peng's binding pancreaticojejunostomy after pancreaticoduodenectomy. An Italian, prospective, dual-institution study. *Pancreatol.* 2013;13(3): 305–309.
19. Kim M, Shin Y, Lee Y, et al. An intuitive method of duct -to -mucosa pancreaticojejunostomy after pancreaticoduodenectomy: use of one-step circumferential interrupted sutures. *Ann Hepato-Biliary-Pancreatic Surg.* 2017;21(1): 39–47.

20. Kaman L, Sanyal S, Behera A, et al. Isolated roux loop pancreaticojejunostomy vs single loop pancreaticojejunostomy after pancreaticoduodenectomy. *International Journal of Surgery*. 2008;6(4): 306-310.
21. Yang H, Dou F, Sharma N, Song J. The methods of reconstruction of pancreatic digestive continuity after pancreaticoduodenectomy: a meta-analysis of randomized controlled trials. *World J. Surg*. 2011;35: 2290–2297.
22. Testini M, Piccinni G, Lissidini G, et al. Surgical management of the pancreatic stump following pancreato-duodenectomy. *Journal of Visceral Surgery*. 2016;153(3): 193–202.
23. Tersigni R, Capaldi M, Ialongo P, et al. Surgical treatment of the pancreatic stump: preventive strategies of pancreatic fistula after pancreatoduodenectomy for cancer. *G Chir*. 2014;35: 213-222.
24. Klaiber U, Probst P, Knebel P, et al. Meta-analysis of complication rates for single-loop versus dual-loop(Roux-en-Y) with isolated pancreaticojejunostomy reconstruction after pancreaticoduodenectomy. *Br. J. Surg*. 2015;102: 331–340.
25. Erdem H, Çetinküner S, Aziret M et al. Can isolated pancreaticojejunostomy reduce pancreas fistula after pancreaticoduodenectomy with Roux-en-Y reconstruction? *Ulus Cerrahi Derg*. 2016;32: 248-251.
26. EL Nakeeb A, Hamdy E, Sultan M, et al. Isolated Roux loop pancreaticojejunostomy versus pancreaticogastrostomy after pancreaticoduodenectomy: a prospective randomized study. *HPB (Oxford)*. 2014;16: 713-722.
27. Keck T, Wellner F, Bahra M, et al. Pancreatogastrostomy versus pancreatojejunostomy for reconstruction after pancreatoduodenectomy: perioperative and long-term results of a multicenter randomized controlled trial. *Ann Surg*. 2016;263(3):440-449.
28. Wellner F, Kulemann B, Lapshyn H, et al. Postpancreatectomy hemorrhage: incidence, treatment, and risk factors in over 1,000 pancreatic resections. *J Gastrointest Surg*. 2014;18: 464–475.
29. Figueras J, Sabater L, Planellas P, et al. Randomized clinical trial of pancreaticogastrostomy versus pancreaticojejunostomy on the rate and severity of pancreatic fistula after pancreaticoduodenectomy. *Br J Surg*. 2013;100(12): 1597-1605.
30. Topal B, Fieuws S, Aerts R, et al. Belgian Section of Hepatobiliary and Pancreatic Surgery. Pancreaticojejunostomy versus pancreaticogastrostomy reconstruction after pancreaticoduodenectomy for pancreatic or periampullary tumours: a multicentre randomised trial. *Lancet Oncol*. 2013;14(7): 655-662.
31. Wada K and Traverso L W. Pancreatic anastomotic leak after the Whipple procedure is reduced using the surgical microscope. *Surgery*. 2006;139(6): 735–742.
32. Strasberg M, Drebin A, Mokadam A, et al. Prospective trial of a blood supply-based technique of pancreaticojejunostomy: effect on anastomotic failure in the Whipple procedure. *Journal of the American College of Surgeons*. 2002;194(6):746–760.
33. Del Chiaro M, Rangelova E, Segersvärd R, et al. Are there still indications for total pancreatectomy? *Updat Surg*. 2016;68: 257.
34. Allen J, Goñen M, Brennan F, et al. Pasireotide for postoperative pancreatic fistula. *N Engl J Med*. 2014;370: 2014–2022.
35. Gans L, van Westreenen L, Kiewiet S, et al. Systematic review and metaanalysis of somatostatin analogues for the treatment of pancreatic fistula. *Br J Surg*. 2012;99: 754–760.